

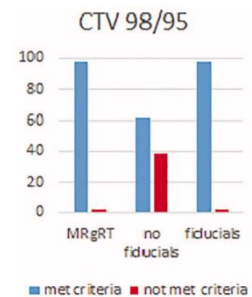
Gold Anchor enables a superior IGRT solution for prostate SBRT

IGRT is standard of care for hypofractionation of the prostate. There are however several ways to perform IGRT and below is a comparison illustrating downsides with other options than Gold Anchor.

	High target dose coverage	Low invasiveness	Resource efficiency
IGRT with Gold Anchor	✓	✓	✓
IGRT with traditional fiducials	✓	✗	✓
CBCT without fiducials	✗	✓	✓
MR-guided daily-adaptive RT	✓	✓	✗

Supporting articles

In [an article published in September 2020](#), authors from the IRCCS Sacro Cuore Don Calabria Hospital in Italy report daily dosimetric variation between MR-guided daily-adaptive RT (MRgRT) and image-guided RT (IGRT) with or without fiducial markers in prostate SBRT. MRgRT and IGRT with fiducials reported no significant prostate CTV underdosage, while IGRT without fiducials was associated with occasional cases of prostate CTV under dosage.



[Another recent study](#), with corresponding author from the Icahn School of Medicine at Mount Sinai, compared 2-dimensional kV orthogonal imaging with fiducial markers (kV-FM) and soft-tissue CBCT (ST-CBCT) for IGRT of prostate.

They concluded that “The kV-FM-based daily image guided alignment for IMRT of prostate cancer is more precise than ST-CBCT, as assessed by a physician’s ability to reproducibly align images. Given the magnitude of the error introduced by inconsistency in making ST-CBCT alignments, these data support a role for daily kV imaging of FM to enhance the precision of external beam dose delivery to the prostate.”

Table 4 Intraobserver variability for test-retest shifts. Mean difference of test-retest shifts±standard deviation (mm)

	kV-FM	ST-CBCT	t test P-value
A-P	0.4 ± 0.7	2.1 ± 2.2	< .0001
L-R	0.4 ± 1.0	1.3 ± 1.4	< .0001
S-I	0.5 ± 0.7	1.2 ± 1.8	< .0001

A-P, anterior-posterior; kV-FM, kV orthogonal imaging with fiducial markers; L-R, left-right; S-I, superior-inferior; ST-CBCT, soft-tissue cone beam computed tomography.